



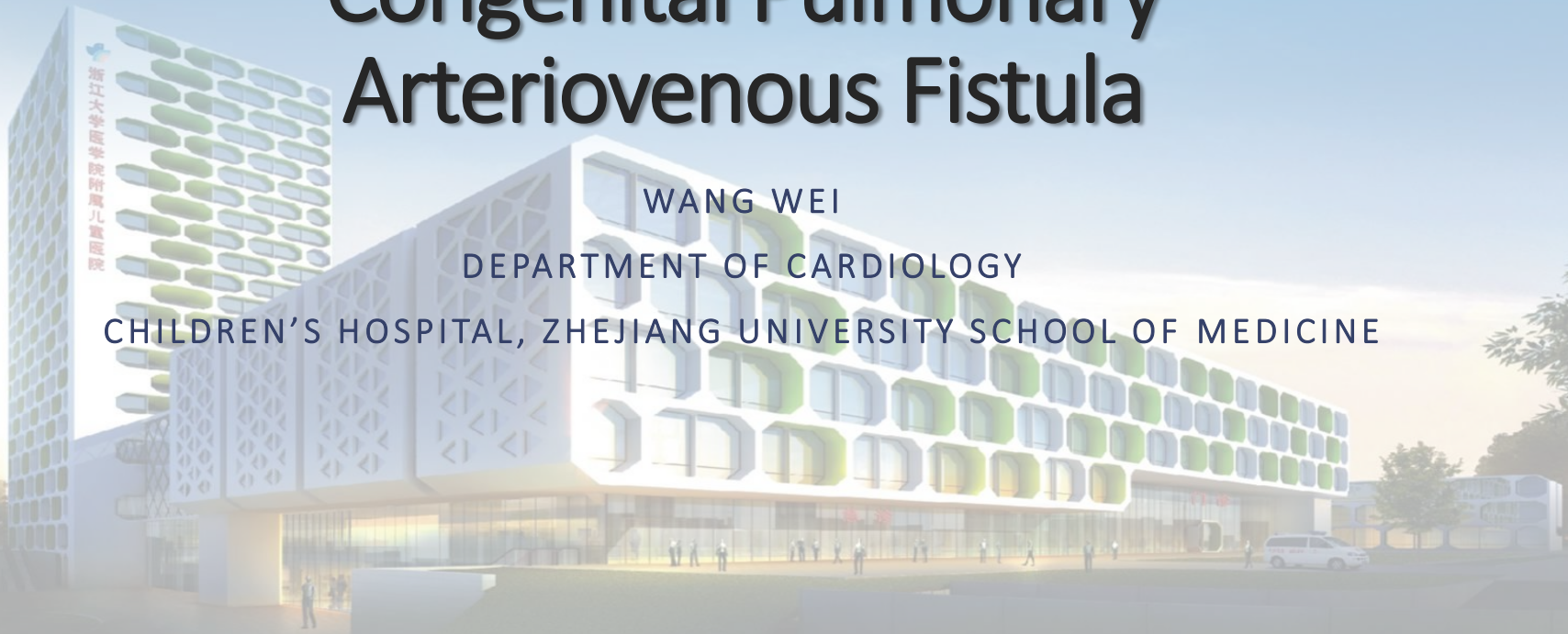浙江大学医学院附属儿童医院
THE CHILDREN'S HOSPITAL
ZHEJIANG UNIVERSITY SCHOOL OF MEDICINE

Delayed Intracranial Air Embolism After Interventional Therapy of Congenital Pulmonary Arteriovenous Fistula

WANG WEI

DEPARTMENT OF CARDIOLOGY

CHILDREN'S HOSPITAL, ZHEJIANG UNIVERSITY SCHOOL OF MEDICINE



Congenital Pulmonary Arteriovenous Fistula(PAVF)

Interventional therapy has been *the first choice* to treat with PAVF especially in patient with multiple lesions:

very safe and effective

But interventional therapy has some complications to be concerned

We report an experience on a 7-year-old boy with a delayed intracranial air embolism after interventional therapy of congenital pulmonary arteriovenous fistula.

To our best knowledge, this was *the first time* this complication has been found the 8th day after interventional therapy of PAVF.

Clinical History

7-year-old boy.

Cyanosis for 6 years and got worse within 3 days.

Also had chest tightness and shortness of breath nearly 3 days, even syncope for one time.

Hemoglobin concentration was 234 g/L.

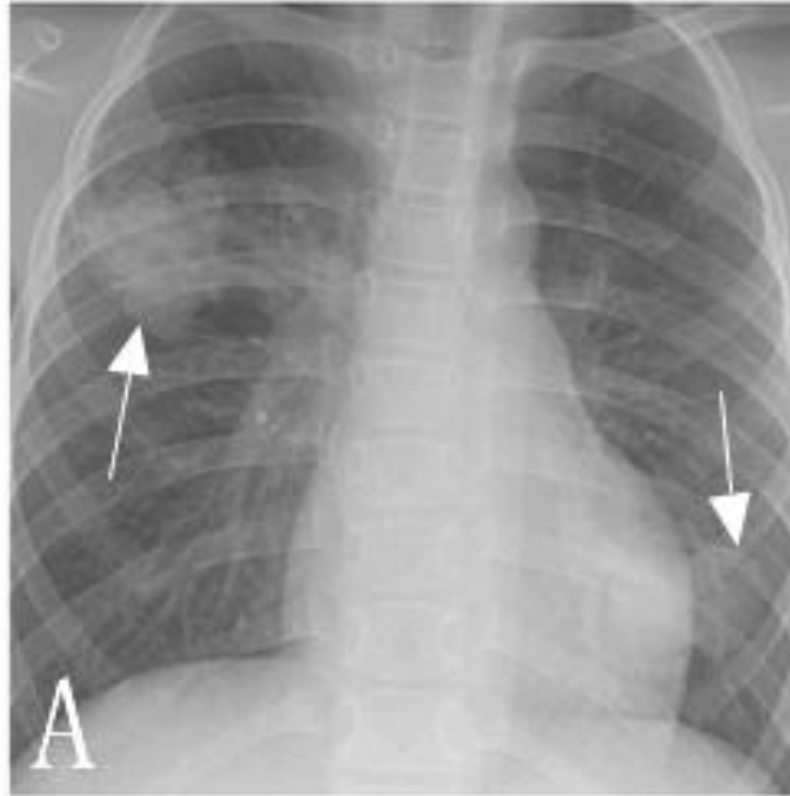
Physical Examination

Height of 117 cm and weight of 18 kg.

Cyanosis, clubbing fingers and no obvious murmur.

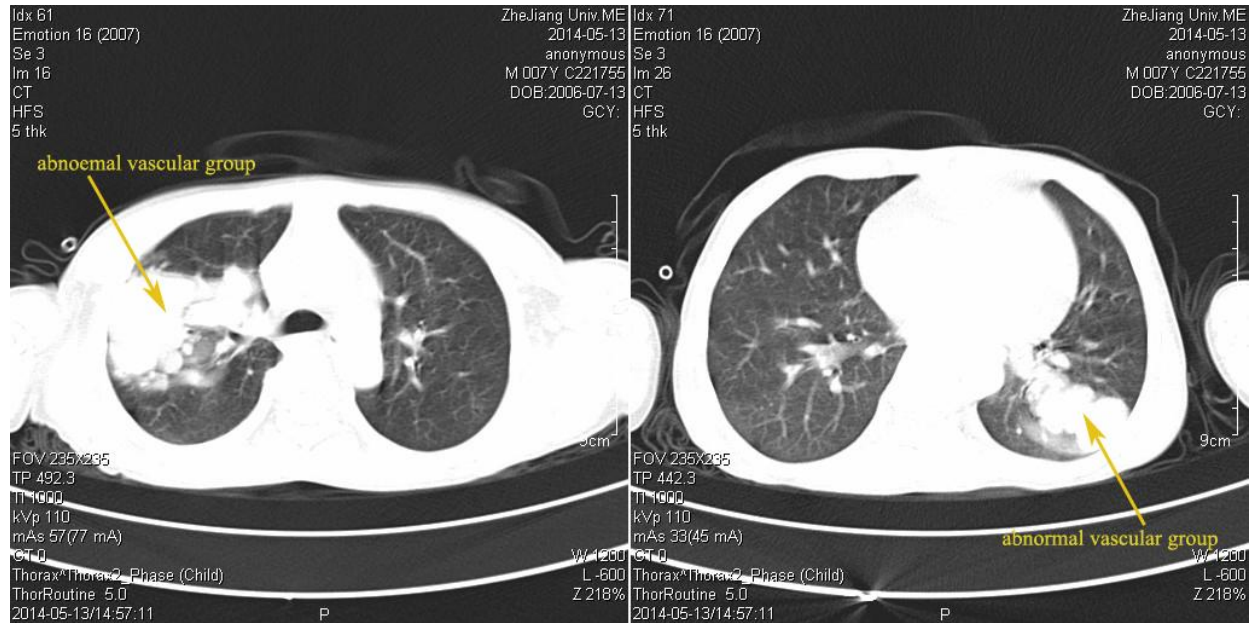The arterial oxygen saturation was 79% in room air.

Imaging Examination



The chest radiograph showed two abnormal opacities in the left lower lobe and the right upper lobe.

Imaging Examination

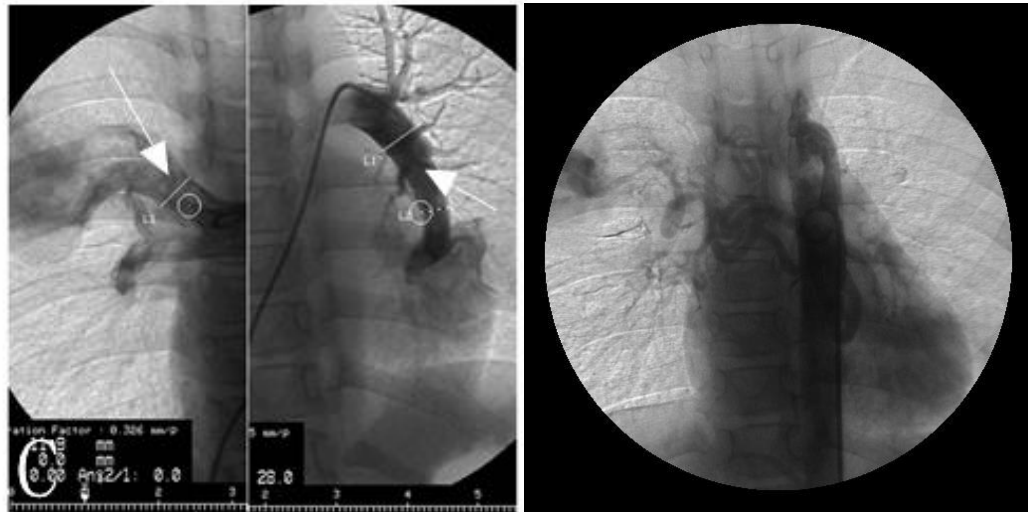


Contrast-enhanced CT showed two abnormal vascular groups in lung.

Cardiac Catheterization

Angiocardiology demonstrated the fistula communications between the main arteries and right pulmonary arteriovenous.

- One abnormal connection was in the right upper lobe (the diameter was 12.1 mm).
- Another was in the left lower lobe (the diameter were 4.5-12mm).
- The other was the main aorto-pulmonary collateral connecting to right pulmonary arteriovenous.



The hemodynamic data were obtained during cardiac catheterization

	before	after
Body surface area (m ²)	0.73	0.73
Weight (Kg)	18	18
Arterial oxygen saturation (SaO ₂)	75.1%	92.0%
Pulmonary arterial pressure (PAP) (mmHg)	22/7(15)	25/10(19)
Right ventricle pressure (RVP) (mmHg)	22/0(8)	25/0(13)
Right atrial pressure (RAP) (mmHg)	7/4(5)	8/4(6)
Inferior vena cava pressure(IVC) (mmHg)	7/3(4)	8/3(5)
Left ventricle pressure (LVP) (mmHg)	90/0(50)	92/0(51)
Ascending aortic pressure (mmHg)	88/64(75)	90/65(78)

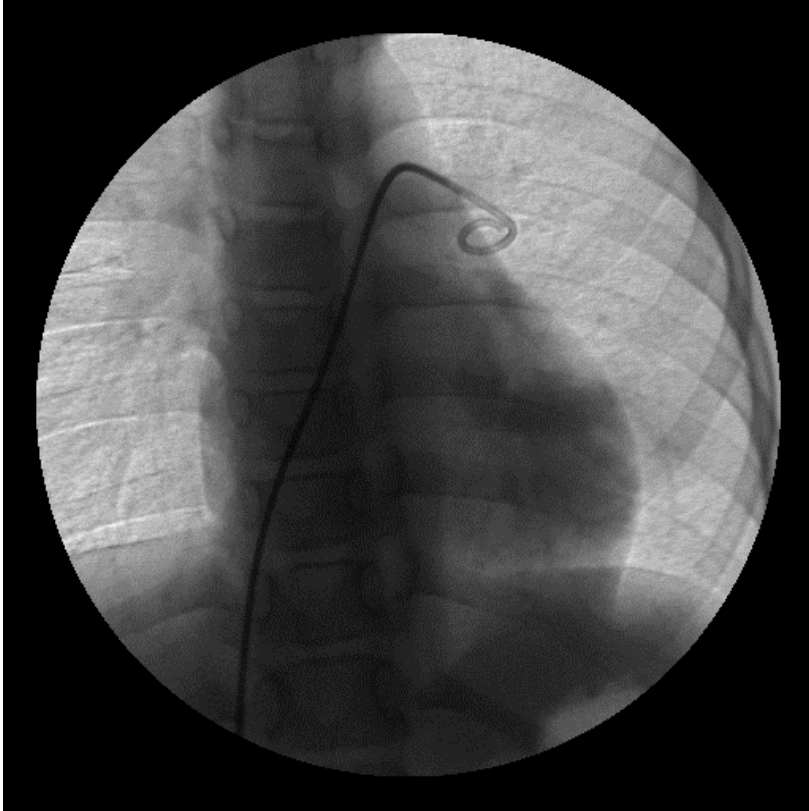
Cardiac Catheterization

The hemodynamic data were obtained during cardiac catheterization

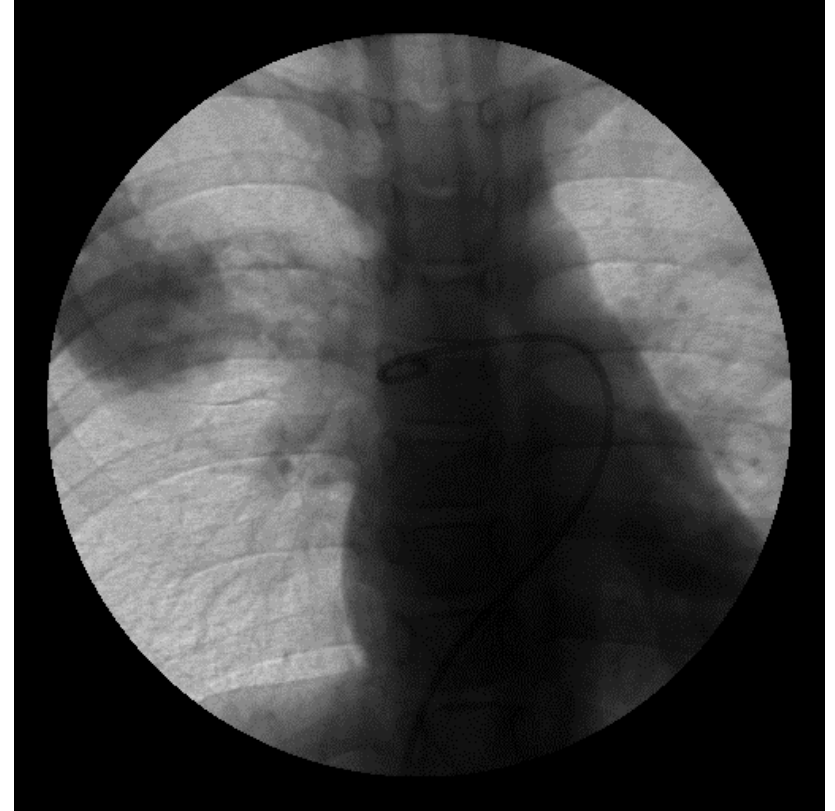
	before	after
Pulmonary-to-systemic pressure ratio (Pp/Ps)	0.25:1	0.28:1
cardiac index (L/min*m2)	5.62	2.60
Pulmonary blood flow (Qp) (L/min)	1.47	1.69
Systemic blood flow (Qs) (L/min)	4.10	1.90
Pulmonary-to-systemic blood flow ratio (Qp/Qs)	0.36:1	0.89:1
Left to right shunt flow (L/min)	0	0
Right to left shunt flow (L/min)	2.63	0.21
Pulmonary vascular resistance(Wood)	10.20	11.26
Systemic vascular resistance(Wood)	17.05	37.93
Pulmonary-to-systemic resistance ratio	0.60:1	0.30:1

Cardiac Catheterization

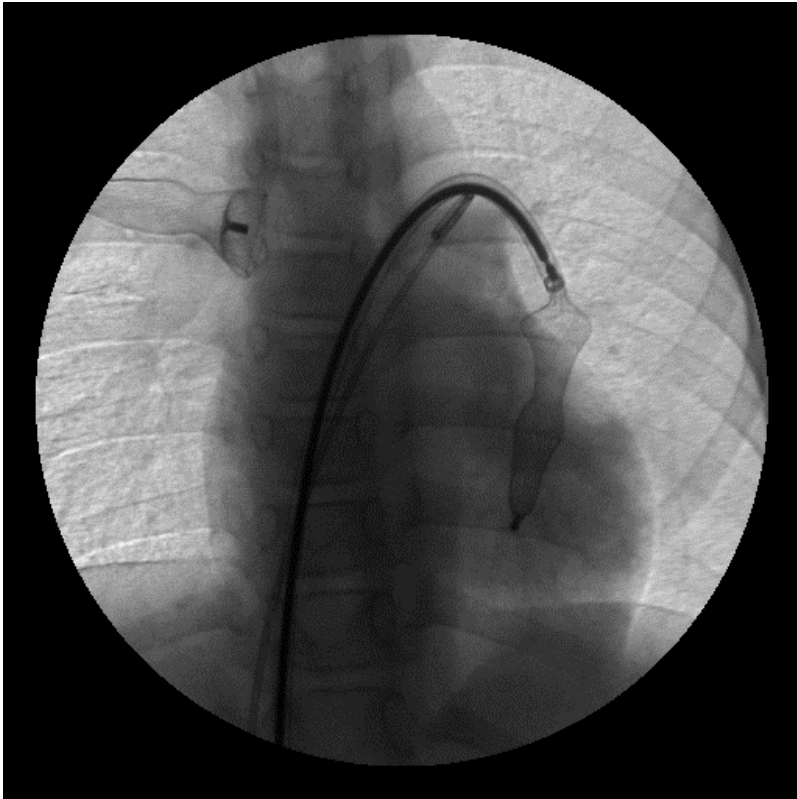
PAVM - LPA



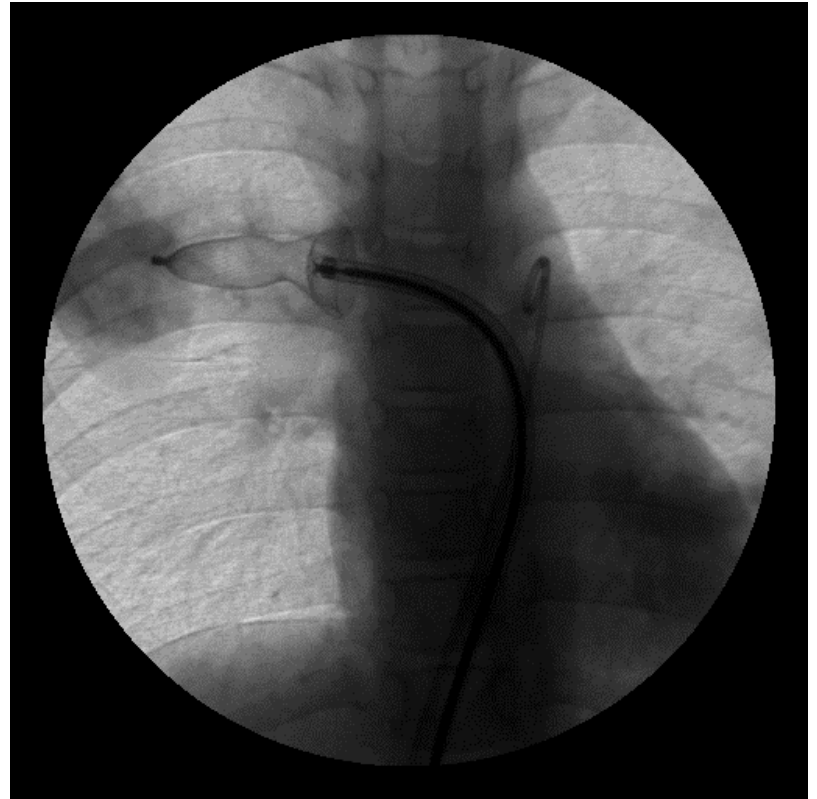
PAVM - RPA



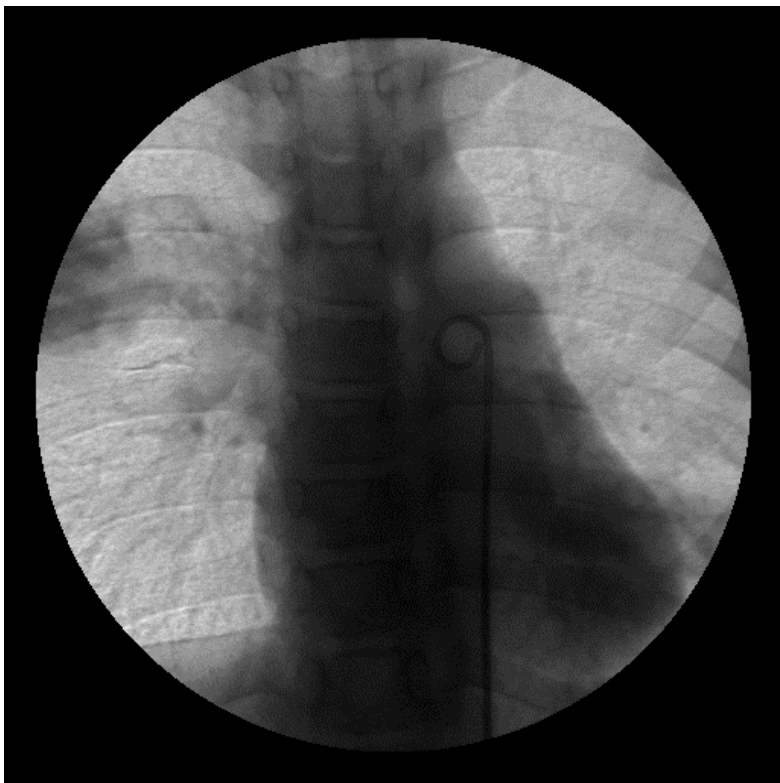
LPA



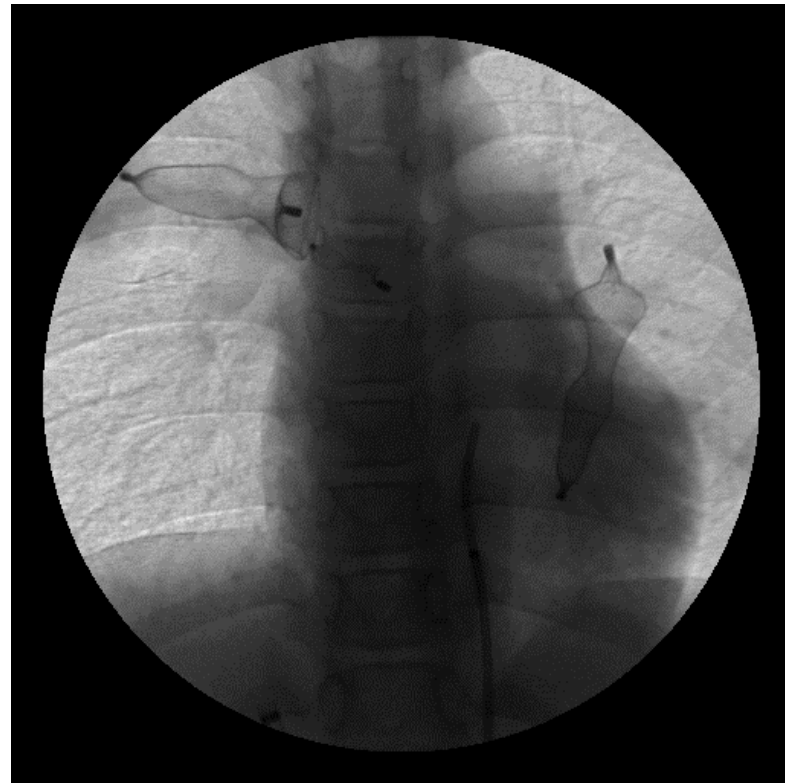RPA



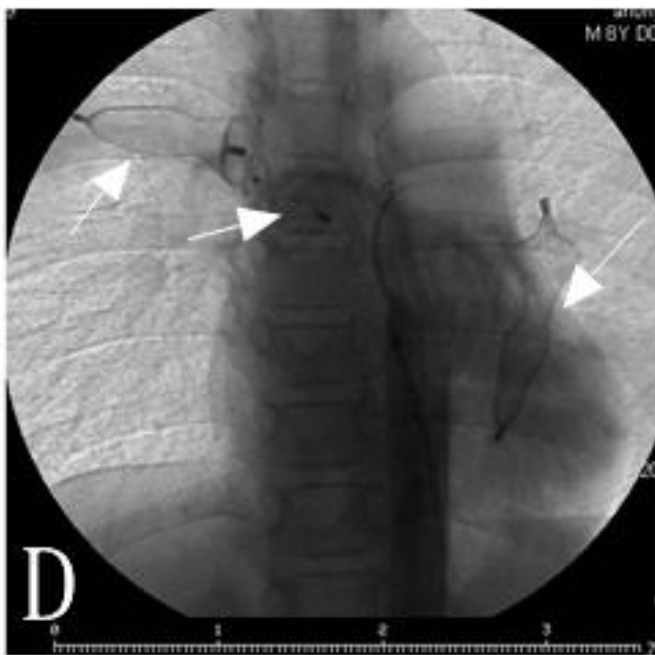PAVM-DAO



DAO



Cardiac Catheterization



- A 22mm Amplatzer Duct Occluder (Shanghai Shape Memory Alloy Co., Ltd) was placed in the right upper lobe.
- A 18mm Amplatzer Duct Occluder (Shanghai Shape Memory Alloy Co., Ltd) was deployed in the left lower lobe.
- A 4*6 Amplatzer Duct Occluder (Lifetech Scientific (Shenzhen) Co., Ltd) was deployed into main aorto-pulmonary collateral.



Cardiac Catheterization

The device was deployed in the fistula and released after an angiogram in the pulmonary artery confirmed satisfactory position. Repeated angiogram showed most of abnormal flows disappeared.

The arterial saturation was immediately increased to 94-95% in room air.

The patient recovered uneventfully until the 8th day after the operation.

8 days later...

A delayed

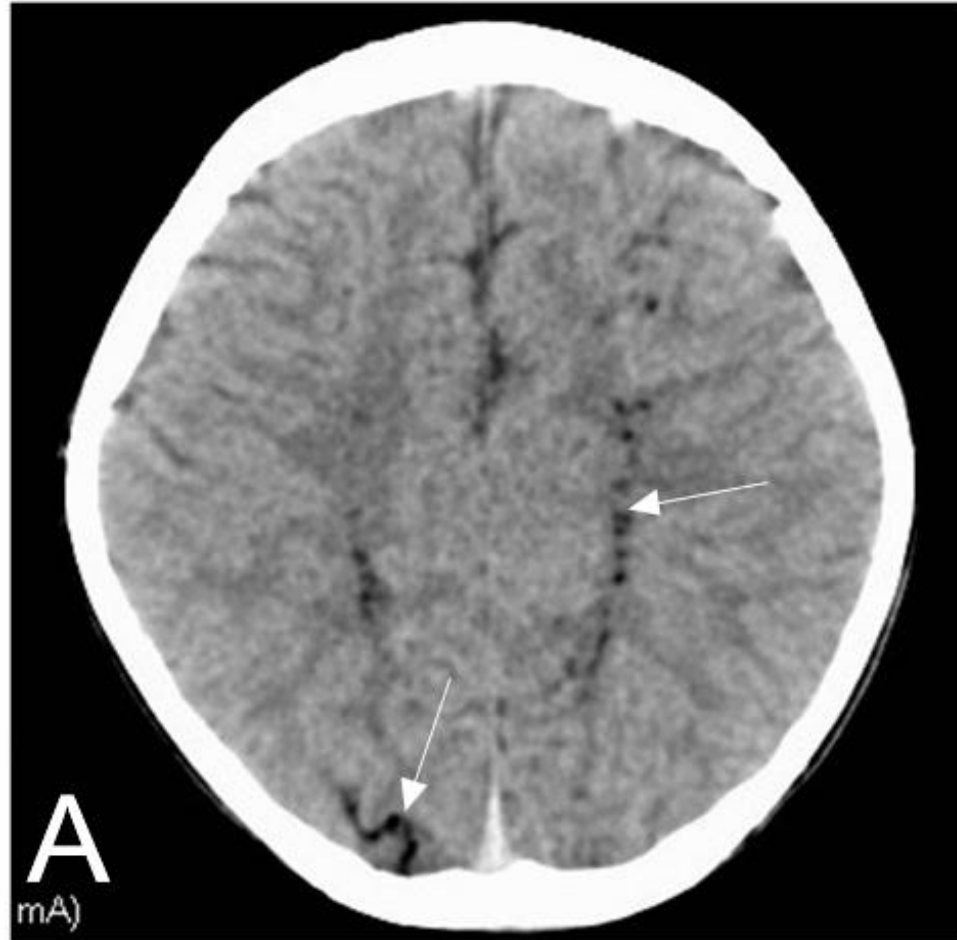Intracranial Air Embolism!



The patient suffered tonic paroxysmal spasm, staring eyes, trismus and unconsciousness for about 1-2 minutes when he was using the toilet.

Imaging Examination

Cranial CT showed sporadic round or lumbricoid air densities, suggestive of air embolism.



Treatment

Midazolam

Trendelenburg position


Oxygen uptake

Low-dose *steroids*

Nifedipine 15ug/kg/h(after
neurologists consultation)

Dextran-40

Mannitol



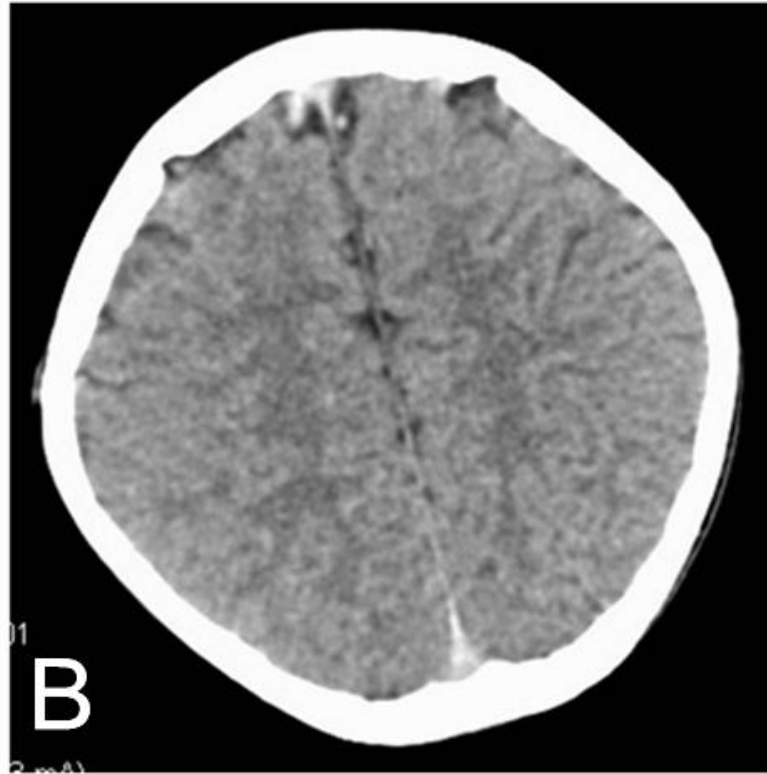
Outcome

Two hours later, the blindness
relieved and the examination
of visual acuity was normal.



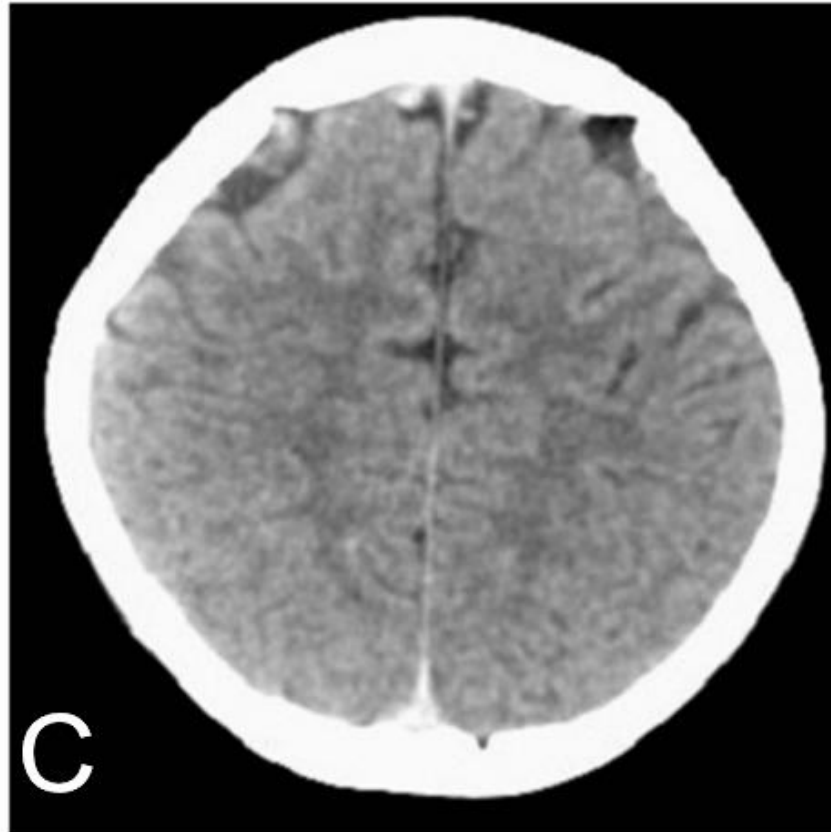
Cranial CT (three hours after
the procedure)

Three hours after the procedure



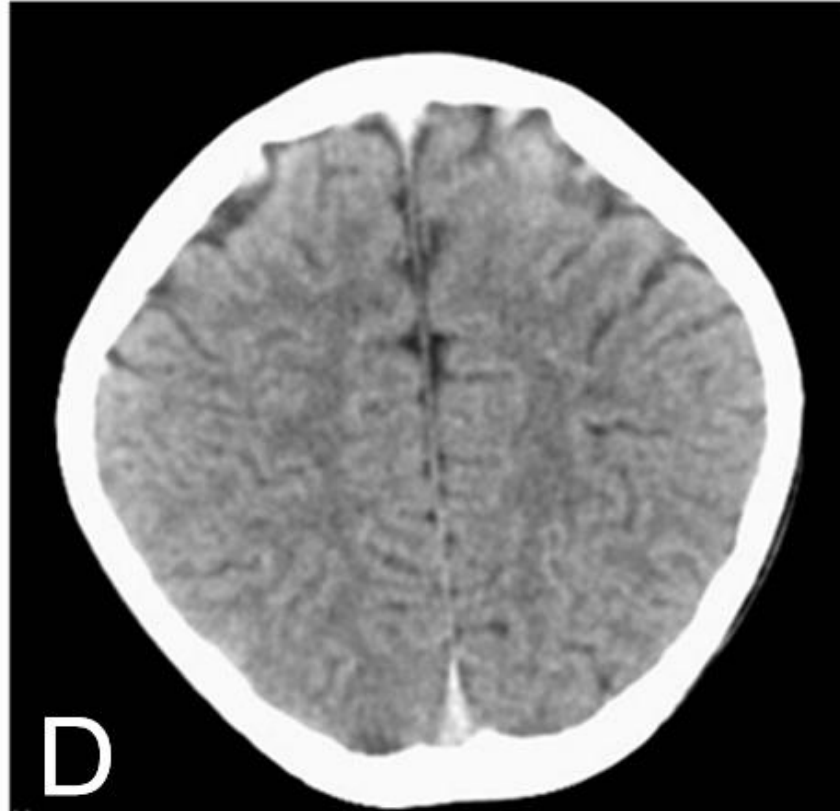
The cranial CT revealed most of the gas disappeared

Four days later



The air embolism was un conspicuous in the cranial CT

Eight days later

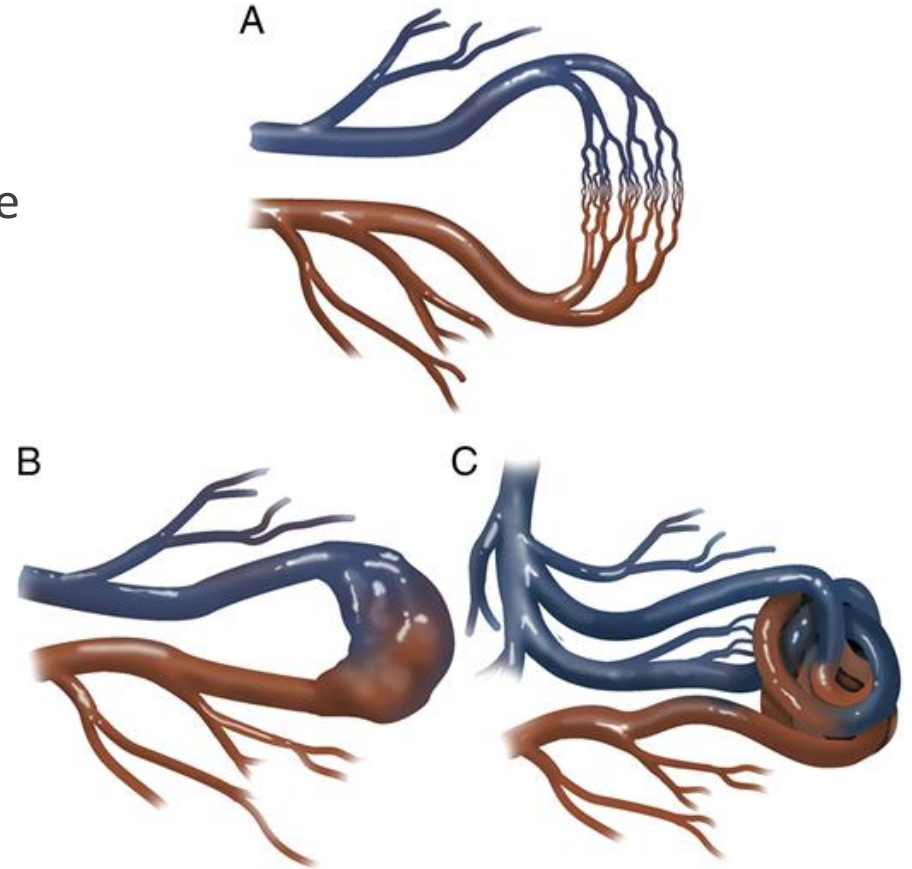


The cranial CT showed none of obvious abnormal but a little deep of sulcus

Pulmonary arteriovenous fistulas (PAVFs)

Definition

- Abnormal communications between the pulmonary arteries and the pulmonary veins.
- Most patients are congenital.
- Can be single, multiple or diffuse.



Michael J., et al. Primary and Acquired Pulmonary Arterial Venous Malformations.

Complications

After transcatheter occlusion

- Haemorrhage
- *Air Embolism (usually immediately after occlusion)*
- Paradoxical embolization
- Migration of implanted device
- Reoccurrence

Our case...

WHY???

- Air entered during operation. although we closed three big fistula, there was still several small fistulas leading abnormal communication between the pulmonary artery and the pulmonary vein without pulmonary capillary. *But why didn't it happen immediately?*
- After operation, because of the same reason. Air entered during transfusion. *But no evidence supports this suspicion.*

Conclusion

Intracranial air embolism should be paid an attention ***even several days*** after interventional therapy of PAVF.

The cause of delayed intracranial air embolism is still not clear.

The clinical manifestations of ***a rapid deterioration of neurologic*** are the important clues for diagnosis, and ***high concentration of oxygen*** is essential for therapy.

THANKS

